

# Hyperbaric Oxygen and Medication-Related Osteonecrosis of the Jaw (MRONJ): An Integrative Review

Oxígeno Hiperbárico y Osteonecrosis de la Mandíbula Relacionada con Medicamentos (MRONJ): Una Revisión Integrada

Mariel Ruivo Biancardi<sup>1</sup>; Luiz Alberto Valente Soares Junior<sup>2</sup>;  
Izabel Regina Fischer Rubira-Bullen<sup>1</sup> & Paulo Sérgio Silva Santos<sup>1</sup>

---

BIANCARDI, M. R.; SOARES JUNIOR, L. A. V.; RUBIRA-BULLEN, I. R. F. & SANTOS, P. S. S. Hyperbaric oxygen and medication-related osteonecrosis of the jaw (MRONJ): An integrative review. *Int. J. Odontostomat.*, 15(4):806-811, 2021.

**ABSTRACT:** Some adjuvant treatments are available for Medication-Related Osteonecrosis of the Jaw (MRONJ) to help the pain and improve quality of life. Among these treatments is hyperbaric oxygen (HBO) which has presented controversial findings in the literature in recent years. This integrative review analyzed the results among studies published during the past 10 years using HBO. The PICO strategy was used and the databases PubMed, LILACS, and SCOPUS. The final search resulted in the inclusion of 7 articles. The main conclusion is that, in the majority of cases, using HBO as an adjuvant to the basic therapy improved the quality of life and/or pain of the patients.

**KEY WORDS:** medication-related osteonecrosis of the jaw, hyperbaric oxygen, MRONJ treatment.

---

## INTRODUCTION

Medication-Related Osteonecrosis of the Jaw (MRONJ) is a relatively recent condition when compared to other types of osteomyelitis found in the jaw, being described for the first time in 2003 (Chiu *et al.*, 2010), and is related to antiresorptive and antiangiogenic drugs used in treatments for cancer and osteoporosis. The American Association of Oral Maxillofacial Surgeons (AAOMS) considers the existence of three concomitant parameters for the diagnosis: 1) current or previous treatment with antiresorptive and/or antiangiogenic drugs; 2) bone exposure or bone that can be probed through an intra or extra oral fistula that persists for 8 or more weeks; 3) no history of radiation to the jaws or metastatic diseases to the jaws (Chiu *et al.*; Ruggiero, 2015; Mücke *et al.*, 2016). The treatments consist of infection control with antibacterial mouth rinses and/or systemic antibiotics and, depending on the extent of the lesion, conservative surgery to eliminate the necrotic bone

(Beth-Tasdogan *et al.*, 2017; El-Rabbany *et al.*, 2017; Otto *et al.*, 2018; de Souza Tolentino *et al.*, 2019).

Hyperbaric oxygen (HBO) is known to help wounds that are unable to heal normally and has been used to treat irradiated maxillary bone since 1973 (Freiberger, 2009; Ceponis *et al.*, 2017). The benefits associated with HBO are the formation of oxygen gradients and reverse of hypoxia environments which can kill leucocytes, important in the healing process (Freiberger *et al.*, 2012). In addition, recent studies pointed out that HBO produces reactive oxygen species (ROS) and reactive nitrogen species (RNS) that aid in the signaling for wound healing (Kitagawa *et al.*, 2019).

Histopathological analysis has shown MRONJ as a condition that causes depletion of osteoclast activity and function, leading to a decrease in bone turnover and wound healing (Freiberger; Chiu *et al.*;

<sup>1</sup> Department of Surgery, Stomatology, Pathology and Radiology, Bauru School of Dentistry of University of Sao Paulo, Brazil (FOB-USP)

<sup>2</sup> Dentistry division of the Hospital da Clínicas of the University of Sao Paulo (HCFMUSP), Brazil.

Kitagawa *et al.*). Since osteoclast activity and functions are regulated by reactive oxygen-sensitive signaling molecules, HBO can be justified as an adjunctive therapy.

HBO is not yet widely considered an efficient treatment for MRONJ as there are a lack of Randomized Control Trials (RCT) on its action, thus, more high-level evidence is needed. An integrative review could clarify the use of HBO as an adjunctive therapy and how it can improve the quality of life (QoL) of patients with MRONJ.

## MATERIAL AND METHOD

The review question “Is hyperbaric oxygen therapy efficient for the management of Medication-Related Osteonecrosis of the Jaw?” was established and the PICO strategy (Population, Intervention, Comparison and Outcome) was defined as: P – patients using antiangiogenics and antiresorptive medications;

I – hyperbaric oxygen sessions; C – only the basic treatment for MRONJ; and O – improvement in the osteonecrosis. We searched the databases PubMed, Lilacs, and Scopus using the descriptors and the Boolean operators “osteonecrosis AND hyperbaric oxygen NOT osteoradionecrosis” to refine our search, including the English and Portuguese literature.

**Selection criteria.** Titles and abstracts were screened for eligibility and duplicates were removed. The period of time of the articles was restricted to 10 years (between 2009 and 2019), since the condition was first described in 2003. We excluded studies with animals, case reports, or other cases/studies of osteonecrosis due to other reasons, not related to medication, and osteonecrosis in parts of the body other than the maxillary bones. Among Randomized Clinical Trials (RCT) we included other reviews and case series that were pertinent to our review.

## RESULTS

The literature search resulted in 111 documents. After removing the duplicates and scanning by title, the final result was 44 records for full assessment. The eligibility criteria were applied, leading to 7 studies included in this review, as shown in the PRISMA flow diagram. Fig. 1.

In this review, all the patients received treatment with bisphosphonate and 83 of whom received treatment with HBO. The underlying pathology found among the studies were osteoporosis (n=36), cancer (n=27), multiple myeloma (n=20) and in all studies included non-specified diseases (n=21). Also, the classification used was the one proposed by the AAOMS, so the stages found were divided in stage 1 (n=3), stage 2 (n=24) and stage 3 (n=15). Some studies followed the method used by Freiberg and colleagues, using only the number and size of the lesions and did not specified the stage (n=62). These numbers are disposed in Table I. The ways of assessing the improvement

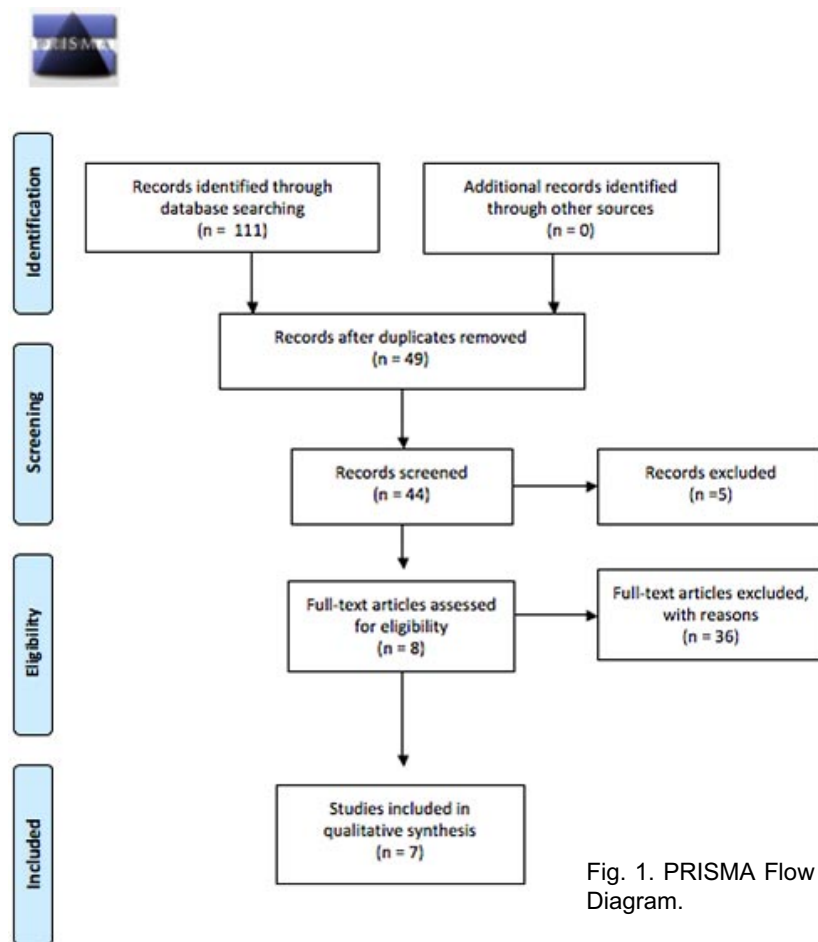


Fig. 1. PRISMA Flow Diagram.

Table I. Patients included in the study, base disease, stage of ON and patients with discontinued medication

	Number of patients
Received HBO	83
Osteoporosis	36
Cancer	27
Multiple Myeloma	20
Others/non specified	21
Stage 1	3
Stage 2	24
Stage 3	15
Non specified	62
Discontinued the medication for treatment	42

of lesions were mostly clinical, however some studies considered histopathological assessment, laboratory tests and quality of life assessment.

All studies reported the lack of consensus on the most efficient treatment for MRONJ and the majority of the interventions used combinations of the

basic treatment consisting of local antiseptic care and antibiotics, associated with an adjunctive therapy, such as HBO, low level laser therapy (LLLTL), or ozone therapy (Rollason *et al.*, 2016; Beth-Tasdogan *et al.*; El-Rabbany *et al.*; de Souza Tolentino *et al.*). The reports considered the debridement or resection surgery for better response of the bone, since this procedure removes the necrotic area. Another controversial issue is the discontinuation of the bisphosphonates, antiresorptive, and/or antiangiogenic drugs: the results observed among the studies demonstrate a more efficient response and decrease in relapses if the drug administration is suspended. However, some patients depend on this medication either because of the cancer condition or autoimmune diseases. The summary of the findings in the included articles is described in Table II.

Although there is no well-defined protocol about the frequency or number of sessions of HBO in the literature, the majority of studies define the dose used as 2ATM. Some studies define the number of sessions according to the stage (Chiu *et al.*), since stages 2

Table II. Summary of the findings, including the protocols used.

Name	Type of study	Exclusive evaluation of HBO?	Protocol	Main Results	How to assess the improvement of the lesions
Chiu <i>et al.</i> , 2010	Case series	Yes	Stage 1: 20 sessions; stages 2 and 3: 20 sessions before and 20 after surgery	Improved symptomatology and clinical aspects of lesions	Clinical
Freiberger <i>et al.</i> , 2012	RCT	Yes	The number of sessions was not specified but therapy was performed 2x/day for 2 hours	Pain relief, decrease in size and number of lesions	Clinical, laboratorial exams and QoL
Rollason <i>et al.</i> , 2016	Systematic Review	No	Not specified	It might improve lesions, but the evidence is too low	Clinical, laboratorial exams and QoL
EL-Rabbany, <i>et al.</i> , 2017	Systematic Review	No	Not specified	Good improvement in lesions, even at a soft tissue level	Clinical, laboratorial exams and QoL
Beth-Tasdogan, <i>et al.</i> , 2017	Systematic Review	No	Not specified	The basic protocol was mandatory for the healing process, which does not prove the efficiency of HBO	Clinical, laboratorial exams and QoL
de Souza Tolentino <i>et al.</i> , 2019	Sytematic Review	No	40 sessions, for 2 hours, 2x/day	Improvement in number and size of lesions	Clinical
Kitagawa, <i>et al.</i> , 2019	Clinical Trial	Yes	20 sessions before and 10 after surgery	HBO is efficient for improving osteoblast activation and inducing mini modeling	FDG-PET + Histopathology

and 3 are most likely to undergo surgery; the patient is submitted to HBO before and after the invasive procedure. All the cases included a basic protocol, consisting of local antiseptic rinse and antibiotics, administered either locally or systemically.

The greatest consensus among the studies was that better designed evaluations are required, with larger samples and longer follow-ups, to produce more reliable evidence on the use of HBO. However, the results of the included studies showed that HBO was efficient for pain relief (Chiu *et al.*; Freiburger *et al.*; EL-Rabbany *et al.*). Some studies also observed a decrease in the size and number of lesions leading to a better clinical outcome (Chiu *et al.*; Freiburger *et al.*; Kitagawa *et al.*). Furthermore, HBO alone is not sufficient to treat MRONJ (Beth-Tasdogan *et al.*; de Souza Tolentino *et al.*).

## DISCUSSION

The AAOMS followed the guidelines of Ruggiero and categorized patients receiving antiresorptive and antiangiogenic treatments. The system consists of: stage 1 – exposed, necrotic bone or fistula that probes to bone with no symptoms or evident infection; stage 2 – exposed, necrotic bone or fistula that probes to bone, associated with infection, pain, and erythema in the regions of the exposed bone, purulent drainage may be present; stage 3 – besides all the clinical features previously described, pathologic fracture, extraoral fistula, oral antral/oral nasal communication, or osteolysis extending to the inferior border or sinus floor are also present.

Since MRONJ was first described in 2003, a lot of classifications about the stages were proposed and the first of them only classified the stages based on clinical examination. But it is also important to consider the bone changes through panoramic radiographic or, even more accurate, computerized tomography. Although, most of the studies about adjunctive therapies or just the hyperbaric oxygen did not consider all the exams necessary to check the improvement. Some of the studies did not even use the scale of stages and just measured the size of the lesions, that is, how much of the exposed bone was covered or at least did not show any sign of infection.

All patients included in this review were on bisphosphonates and had cancer, osteoporosis or

multiple myeloma. Also, some studies had a group defined as “others” or “non specified” which is also a risk of bias since the doses and frequency of the medication in these groups are different. Furthermore, when it comes to the best optimal situation for HBO efficacy, the key is always referred to as discontinuing medication, but in some patients, it could cause more harm than good, like the osteoporosis patients who sometimes use the drugs until the end of their lives.

Treatments for MRONJ are scarce and controversial and there is no consensus in the literature, however, a combination of basic and adjunct treatments is generally used, as there is no well-defined evidence-based protocol for this condition (Beth-Tasdogan *et al.*; EL-Rabbany *et al.*; de Souza Tolentino *et al.*). The basic protocol consists of local irrigation with antimicrobial agents, the use of antibiotics, and debridement or surgical resection (de Souza Tolentino *et al.*). A few adjuvant therapies are cited in the literature, such as low-level laser therapy, ozone therapy, and hyperbaric oxygen, but high levels of scientific evidence are still needed to prove their efficacy (Beth-Tasdogan *et al.*; EL-Rabbany *et al.*; de Souza Tolentino *et al.*). Although there is not enough scientific evidence to support a single efficient treatment protocol for MRONJ, it is possible to notice a consensus among all the current studies and reviews on the subject regarding the need to perform surgical debridement combined with antibiotics. Another point that seems to be important in the face of new investigations is the issue of the suspension of anti-resorptive and/or anti-angiogenic medication in order to completely regress the condition.

Since 1973, HBO has been used to prepare irradiated patients for teeth extraction, a protocol known as “the Marx protocol” (Beth-Tasdogan *et al.*; Shaw *et al.*, 2019). The main reason why HBO is used to treat infections in the jaws – and other sites - is that among its known mechanisms is the inhibition of anaerobic microorganisms. Recent studies have shown that HBO can improve bone health, including working to decrease osteoclasts (Spiegelberg *et al.*, 2010). Moreover, the reactive oxygen combined with nitrogen species that are produced during the process lead to a positive intracellular modulation involved in bone turnover (Freiburger *et al.*). Despite the fact that there is no consensus on an efficient protocol, since more studies with a higher level of evidence are needed, all the included studies showed improvement in painful symptoms and general quality of life of patients with lesions.

Systematic reviews on the management of osteonecrosis of the jaw demonstrate that there are no studies which consider HBO as a single therapy and all the mentioned adjunctive therapies are considered during or after the basic protocol has been applied (Rollason *et al.*; Beth-Tasdogan *et al.*; EL-Rabbany *et al.*; de Souza Tolentino *et al.*). There is also a lack of consensus about the number of sessions, with protocols varying between 20 and 40, but always at 2 atmospheres (ATM). All the reviews reported positive results for controlling the symptoms or decreasing the size of the lesions. In addition, HBO is considered an option in MRONJ cases even though studies with larger samples, longer follow-ups, and more details about the sessions should be conducted to increase the confidence and level of evidence of this therapy in these cases (Shaw *et al.*).

The study performed by Kitagawa *et al.*, used FDG-PET to evaluate metabolic alterations in bone tissue activity before and after HBO therapy in ORN and MRONJ. The evaluation showed a decrease in inflammatory response in stage 1 after the HBO sessions and signs of bone remodeling after the debridement surgery associated with before and after HBO but no differences were noticed in stage 2. Histopathological findings could be a tool to confirm the FDG-PET hypothesis, since it only evaluates the metabolic changes in cells and the analysis of the specimens after HBO therapy demonstrated that there were new bone area activating osteoblasts and modeling with pre-existing old bone. These results were not observed in ORN cases. This was the first study to demonstrate the efficiency of HBO for MRONJ through histological tests (Kitagawa *et al.*).

It is important to check the oral health status in each patient even before performing any kind of treatment since any focus of infection can lead to osteonecrosis of the jaws even without invasive procedures, occurring spontaneously. Still, all adjunctive therapies seem to work at least to alleviate painful symptoms, however there is still insufficient evidence to assess which one (LLLT, HBO, ozone therapy) is the most efficient for the complete cure of this condition, especially due to the fact that better results have appeared with the discontinuation of medication and in many patients this is not possible.

**CONCLUSION.** Although there is a lack of high-quality evidence justifying the use of HBO – as any other adjunctive therapies – with incomplete protocols to

establish a conclusion, the clinical experience demonstrates improvement in symptomatology through this adjunctive therapy, leading to better quality of life. Furthermore, HBO alone does not guarantee the healing process.

---

**BIANCARDI, M. R.; SOARES JUNIOR, L. A. V.; RUBIRA-BULLEN, I. R. F. & SANTOS, P. S. S.** Oxígeno hiperbárico y osteonecrosis de la mandíbula relacionada con medicamentos (MRONJ): Una revisión integrada. *Int. J. Odontostomat.*, 15(4):806-811, 2021.

**RESUMEN:** Existen algunos tratamientos adyuvantes para la osteonecrosis de la mandíbula relacionada con medicamentos (MRONJ) para aliviar el dolor y mejorar la calidad de vida de los pacientes. Entre estos tratamientos se encuentra el oxígeno hiperbárico (OHB) que ha presentado resultados controvertidos en la literatura durante los últimos años. En esta revisión integrada se analizaron los resultados de los estudios publicados durante los últimos 10 años utilizando OHB. Se utilizó la estrategia PICO y las bases de datos PubMed, LILACS y SCOPUS. La búsqueda final resultó en la inclusión de 7 artículos. La principal conclusión es que, en la mayoría de los casos, el uso de OHB como adyuvante de la terapia básica mejoró la calidad de vida y / o el dolor de los pacientes.

**PALABRAS CLAVE:** osteonecrosis de la mandíbula relacionada con medicamentos, oxígeno hiperbárico, tratamiento con MRONJ.

---

## REFERENCES

- Beth-Tasdogan, N. H.; Mayer, B.; Hussein, H. & Zolk, O. Interventions for managing medication-related osteonecrosis of the jaw. *Cochrane Database Syst. Rev.*, 10(10):CD012432, 2017.
- Ceponis, P.; Keilman, C.; Guerry, C. & Freiburger, J. J. Hyperbaric oxygen therapy and osteonecrosis. *Oral Dis.*, 23(2):141-51, 2017.
- Chiu, C. T.; Chiang, W. F.; Chuang, C. Y. & Chang, S. W. Resolution of oral bisphosphonate and steroid-related osteonecrosis of the jaw--a serial case analysis. *J. Oral Maxillofac. Surg.*, 68(5):1055-63, 2010.
- de Souza Tolentino, E.; de Castro, T. F.; Michellon, F. C.; Passoni, A. C. C.; Ortega, L. J. A.; Iwaki, L. C. V. & da Silva, M. C. Adjuvant therapies in the management of medication-related osteonecrosis of the jaws: Systematic review. *Head Neck*, 41(12):4209-28, 2019.
- EL-Rabbany, M.; Sgro, A.; Lam, D. K.; Shah, P. S. & Azarpazhooh, A. Effectiveness of treatments for medication-related osteonecrosis of the jaw: A systematic review and meta-analysis. *J. Am. Dent. Assoc.*, 148(8):584-594.e2, 2017.
- Freiburger, J. J. Utility of hyperbaric oxygen in treatment of bisphosphonate-related osteonecrosis of the jaws. *J. Oral Maxillofac. Surg.*, 67(5 Suppl.):96-106, 2009.
- Freiburger, J. J.; Padilla-Burgos, R.; McGraw, T.; Suliman, H. B.; Kraft, K. H.; Stolp, B. W.; Moon, R. E. & Piantadosi, C. A. What is the role of hyperbaric oxygen in the management of

- bisphosphonate-related osteonecrosis of the jaw: a randomized controlled trial of hyperbaric oxygen as an adjunct to surgery and antibiotics. *J. Oral Maxillofac Surg.*, 70(7):1573-83, 2012.
- Kitagawa, Y.; Ohga, N.; Asaka, T.; Sato, J.; Hata, H.; Helman, J.; Tsuboi, K.; Amizuka, N.; Kuge, Y. & Shiga, T. Imaging modalities for drug-related osteonecrosis of the jaw (3), Positron emission tomography imaging for the diagnosis of medication-related osteonecrosis of the jaw. *Jpn. Dent. Sci. Rev.*, 55(1):65-70 2019.
- Mücke, T.; Krestan, C. R.; Mitchell, D. A.; Kirschke, J. S. & Wutzl, A. Bisphosphonate and medication-related osteonecrosis of the jaw: a review. *Semin. Musculoskelet. Radiol.*, 20(3):305-14, 2016.
- Otto, S.; Pautke, C.; Van den Wyngaert, T.; Niepel, D. & Schiødt, M. Medication-related osteonecrosis of the jaw: Prevention, diagnosis and management in patients with cancer and bone metastases. *Cancer Treat. Rev.*, 69:177-87, 2018.
- Rollason, V.; Laverrière, A.; MacDonald, L. C. I.; Walsh, T.; Tramèr, M. R. & Vogt-Ferrier, N. B. Interventions for treating bisphosphonate-related osteonecrosis of the jaw (BRONJ). *Cochrane Database Syst. Rev.*, 2(2):CD008455, 2016.
- Ruggiero, S. L. Diagnosis and Staging of Medication-Related Osteonecrosis of the Jaw. *Oral Maxillofac. Surg. Clin. North Am.*, 27(4):479-87, 2015.
- Shaw, R. J.; Butterworth, C. J.; Silcocks, P.; Tesfaye, B. T.; Bickerstaff, M.; Jackson, R.; Kanatas, A.; Nixon, P.; McCaul, J.; Praveen, P.; et al. HOPON (Hyperbaric Oxygen for the Prevention of Osteoradionecrosis): A Randomized Controlled Trial of Hyperbaric Oxygen to Prevent Osteoradionecrosis of the Irradiated Mandible After Dentoalveolar Surgery. *Int. J. Radiat. Oncol. Biol. Phys.*, 104(3):530-9, 2019.
- Spiegelberg, L.; Djasim, U. M.; van Neck, H. W.; Wolvius, E. B. & van der Wal, K. G. Hyperbaric oxygen therapy in the management of radiation-induced injury in the head and neck region: a review of the literature. *J. Oral Maxillofac. Surg.*, 68(8):1732-9, 2010.

Corresponding author:  
Mariel Ruivo Biancardi  
Department of Surgery  
Stomatology, Pathology and Radiology  
Bauru School of Dentistry - University of São Paulo  
Al. Dr. Octávio Pinheiro Brisolla, 9-75  
Bauru - São Paulo  
CEP 17012-901  
BRAZIL

E-mail: marielbiancardi@usp.br