

# Bilateral Communications of the Paralingual Space

## Comunicaciones Bilaterales del Espacio Paralingual

Pablo Jara González; Mario Cantín López; Bernarda López Farías;  
Sandoval Marchant Catherine & Iván Suazo Galdames

---

JARA, G. P.; CANTÍN, L. M.; LÓPEZ, F. B.; SANDOVAL, M. C. & SUAZO, G. I. Bilateral communications of the paralingual space. *Int. J. Odontostomat.*, 2(1):67-70, 2008.

**ABSTRACT:** Paralingual Space is a region located on the floor of the oral cavity. The cavity has great importance in communications and for the spread of infectious diseases. This study investigated the level of dissemination of 0.2 ml of an oily pigment solution, into paralingual space of 20 heads of male Sprague Dawley rats. The results can be seen by the spread of the solution in the three segments of paralingual space, being higher in the middle third of the region, although the differences were not significant ( $p < 0.05$ ). With these observations, the discussion is about the possibility that an infection may spread into paralingual space opposite the muscles of the medial wall of this space.

**KEY WORDS:** paralingual space, hiatus of Fleischmann, genioglossus muscle, hyoglossus muscle.

---

## INTRODUCTION

The paralingual space is a coupled space, located between the muscles of the tongue medially, mandible, laterally and anteriorly, in the lower mylohyoid muscle, and in the higher oral mucosa (Kim *et al.*, 2004; Latarjet & Ruiz-Liard, 2004). The cavity gets this name for the anatomical area that is in direct relation to the tongue and anatomical structures adjacent to it. This space can be inspected when analyzing the floor of the oral cavity, where the first thing to strike is the dorsal side of the tongue, but also if tip of the tongue is tractioned toward higher notes the lower side normally rests in a triangular shape, and is extended from the gingival area to the base of tongue. This area presents a vertex, directed toward anterior and is located behind the incisors, in contrast, it is based on the triangle toward the distal and corresponds to the most posterior area of the lower side of the tongue; the two sides are limited to the right and left of the dental arch.

The paralingual space extends deep into the mylohyoid muscle (Castelli *et al.*, 1969) that separates it from the suprahyoid region; on its higher wall the paralingual space is covered by the oral mucosa.

The medial wall of the paralingual space consists of genioglossus and hyoglossus muscles, which presents a fasciculated aspect (Kruger, 1983).

Paralingual space is importance because it provides communication with surrounding structures such as the submandibular, pterygomandibular, pterygopharyngeal, and submental space. Besides this, it is engaged as a kind of surgical clinic; infectious processes that occur in any of these paralinguals areas can drain or disseminate to other areas and infect them too, thus causing an increasingly complex clinical situation with difficult resolution and may even endanger the patient's life (Lepore, 1976; Gonzalez-Garcia *et al.*, 2006; Flynn *et al.*, 2006). In addition to communications to different regions of the head and neck, communication with the opposite paralingual space is done only through a small triangular hiatus that is limited by the oral mucosa, the jaw, and genioglossus muscle fibers; this restraining is known as hiatus of Fleischmann (Testut, 1981).

An infection that is caused by resistance to treatments or aggressive antibiotic microorganisms commonly used and which commits both paralinguals spaces (Gay & Berini, 1999) through the hiatus of Fleishman, causes the upward and back displacement of the tongue, displacing the epiglottis on the ostium pharyngeum, thus obstructing breathing (Kremer & Blair, 2006). The patency of the airway to be committed causes the patient to begin to suffocate (Yonetsu *et*

*al.*, 1998; Arijji *et al.*, 2002; Niederhauser *et al.*, 2006). The purpose of this study was to analyse the levels of dissemination of an oily solution the consistency of which was similar to that of an infectious process through the medial wall of the paralingual space.

## MATERIAL AND METHOD

Twenty heads of adult female Sprague-Dawley rats, weighing 250-300 gr without obvious morphological alterations were used. This study was conducted in the laboratory of anatomy at the Universidad de Talca, Chile.

The rats were injected with 0.2 ml colored oily solution in the paralingual space, similar in consistency to that of an infectious process, according to the technique described by Jabour *et al.*, (1993). The point of puncture was located in the gingivolingual fovea at a distance of 1 cm distal to the distal side of the lower central incisor of the rats. The injected heads were placed for 24 hours in a 45° angle between the axis and the biaural axial plane.

Subsequently, the heads were put in a cold chamber for 48 h. After this time, the heads were cut horizontally along the tongue, which provided blocks of the lower end of the head that included the tongue and paralingual space. On these blocks were made three coronal cuts with a distance of 2.5mm between them, measured from the lingual surface of the lower incisors, obtaining three segments (Fig. 1):

Segment A: anterior third of paralingual space.  
Segment B: middle third of paralingual space.  
Segment C: posterior third paralingual space.

In each segment, the posterior side was marked and the level of dissemination of colored oily solution to the opposite side was measured using a digital caliper (0.01mm), taking as zero point the median line.

The results were analysed using the SPSS 11.5 software and descriptive statistics were obtained from the sample. The statistical significance of differences in the means of dissemination in the three levels of the paralingual space was analyzed using the t-test with  $p < 0.05$ .

## RESULTS

The largest dissemination was found in segment B (middle third of the paralingual space), with an average of 1.325 mm (SD 0.5), followed by segment C (posterior third of the paralingual space, with a mean of 1.2 mm (SD 0.44), whereas less dissemination was noted in segment A (anterior third of the paralingual space) with a mean of 1.14 mm (SD 0.69) (Fig. 2).

There were no significant differences ( $p < 0.05$ ) in the mean diffusion in the three segments of paralingual space.

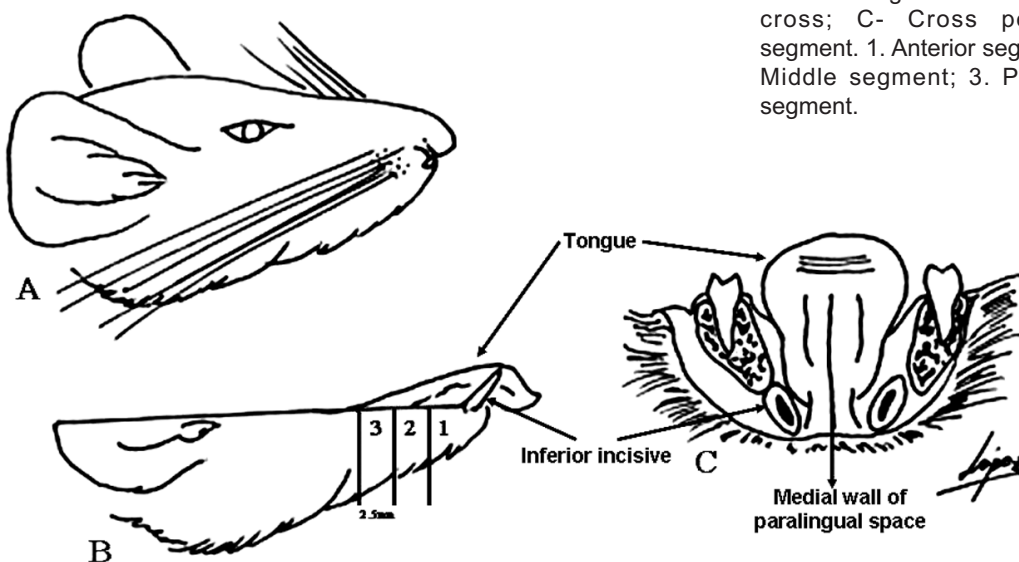


Fig. 1 : A- Sprague Dawley rats; B- Lower segment of the rat with cross; C- Cross posterior segment. 1. Anterior segment; 2. Middle segment; 3. Posterior segment.

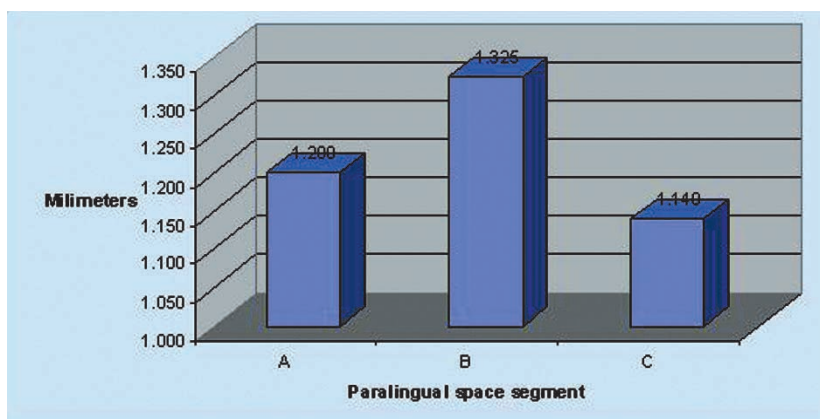


Fig. 2. Graphic shows level of dissemination in each segment.

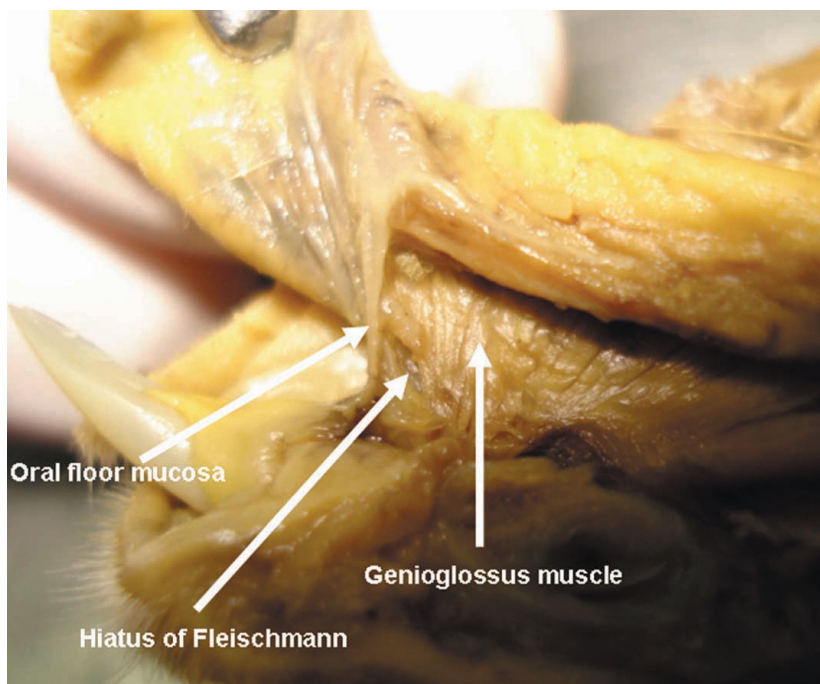


Fig. 3. Medial wall of paralingual space.

## DISCUSSION

The paralingual space is an important area on the floor of the oral cavity, which establishes communications with the submandibular, pterygomandibular, pterygopharyngeal, and submental and the opposite paralingual space (Castelli *et al.*), and is a high-risk site for the dissemination of infectious processes (Prágai, 1976; Testut; Yasumoto *et al.*, 1993; Klepacek & Skulec, 1994; Gay & Berini; Figún & Garino, 2001; Latarjet & Ruiz-Liard, Pogrel & Goldman, 2004).

This study analyzed the level of dissemination of an pigmented oily solution, with a consistency similar to that of an abscess. The results

show that there was diffusion in three-thirds of the paralingual space, This disagrees with the majority of authors and classical anatomical descriptions indicating that the paralingual space communicates with the opposite side only through the hiatus of Fleischmann, located in the anterior third of the region, although, in segments beyond the presence of genioglossus and hyoglossus muscle, and over the whole of the muscle mass of the tongue, hyoglossus membrane, and lingual septum, the dissemination of infectious diseases is hampered. However, the fasciculated characteristic in muscles of the medial wall of the paralingual space (Fig. 3), does not appear to constitute an effective obstacle for the dissemination of the colored oily solution injected into the paralingual space of rats in this study.

JARA, G. P.; CANTÍN, L. M.; LÓPEZ, F. B.; SANDOVAL, M. C. & SUAZO, G. I. Comunicaciones bilaterales del espacio paralingual. *Int. J. Odontostomat.*, 2(1):67-70, 2008.

**RESUMEN:** El espacio paralingual es una región ubicada en el piso de la cavidad oral con comunicaciones de gran importancia para la difusión de procesos infecciosos. El presente estudio investigó el nivel de difusión de 0,2 ml de una solución oleosa pigmentada, hacia el espacio paralingual opuesto en 20 cabezas de ratas Sprague Dawley. En los resultados obtenidos se observa la difusión de la solución en los tres segmentos del espacio paralingual, siendo mayor en el tercio medio de la región, aunque las diferencias no resultaron significativas ( $p < 0,05$ ). Con estas observaciones se discute acerca de la posibilidad de que un proceso infeccioso pueda difundir hacia el espacio paralingual opuesto a través de la musculatura de la pared medial del espacio.

**PALABRAS CLAVE:** espacio paralingual, hiato de Fleischmann, músculo geniogloso, músculo hiogloso.

## REFERENCES

- Ariji, Y.; Gotoh, M.; Kimura, Y.; Naitoh, M.; Kurita, K.; Natsume, N. & Ariji, E. Odontogenic infection pathway to the submandibular space: imaging assessment. *Int. J. Oral Maxillofac. Surg.*, 31(2):165-9, 2002.
- Castelli, W. A.; Huelke, D. F. & Celis, A. Some basic anatomic features in paralingual space surgery. *Oral Surg. Oral Med. Oral Pathol.*, 27(5):613-21, 1969.
- Figún, M. & Garino, R. *Anatomía Odontológica Funcional y Aplicada*. 2ª ed. El Ateneo, Buenos Aires, 2001.
- Flynn, T. R.; Shanti, R. M.; Levi, M. H.; Adamo, A. K.; Kraut, R. A. & Trieger, N. Severe odontogenic infections, part 1: prospective report. *J. Oral Maxillofac. Surg.*, 64(7):1093-103, 2006.
- Gay, C. & Berini, L. *Cirugía Bucal*. Ediciones Erbon, Madrid, 1999.
- Gonzalez-Garcia, R.; Schoendorff, G.; Munoz-Guerra, M. F.; Rodriguez-Campo, F. J.; Naval-Gias, L. & Sastre-Perez, J. Upper airway obstruction by sublingual hematoma: a complication of anticoagulation therapy with acenocoumarol. *Am. J. Otolaryngol.*, 27(2):129-32, 2006.
- Jabour, B. A.; Choi, Y.; Hoh, C. K.; Rege, S. D.; Soong, J. C.; Lufkin, R. B.; Hanafee, W. N.; Maddahi, J.; Chaiken, L.; Bilet, J.; Phelps, M. E.; Hawkins, R. A. & Abemeyor, E. Extracranial head and neck: PET imaging with 2-[F-18]fluoro-2-deoxy-D-glucose and MR imaging correlation. *Radiology*, 186(1):27-35, 1993.
- Kim, S. Y.; Hu, K. S.; Chung, I. H.; Lee, E. W. & Kim, H. J. Topographic anatomy of the lingual nerve and variations in communication pattern of the mandibular nerve branches. *Surg. Radiol. Anat.*, 26(2):128-35, 2004.
- Klepceck, I. & Skulec, R. Relation between lingual nerve, submandibular gland duct and mandibular body in the sublingual space. *Acta Chir. Plast.*, 36(1):26-7, 1994.
- Kremer, M. J. & Blair, T. Ludwig angina: forewarned is forearmed. *AANA J.*, 74(6):445-51, 2006.
- Kruger, E. Advances and focal points in oro-maxillofacial surgery. *Quintessenz*, 4(9): 1655-70, 1983.
- Latarjet, M. & Ruiz-Liard, A. *Atlas de Anatomía*. 2ª ed. Editorial Panamericana, Buenos Aires, 2004.
- Lepore, M. L. Upper airway obstruction induced by warfarin sodium. *Arch Otolaryngol.*, 102(8):505-6, 1976.
- Niederhauser, A.; Kirkwood, D.; Magann, E. F.; Mullin, P. M. & Morrison, J. C. Ludwig's angina in pregnancy. *J. Matern. Fetal Neonatal Med.*, 19(2):119-20, 2006.
- Pogrel, M. A. & Goldman, K. E. Lingual flap retraction for third molar removal. *J. Oral Maxillofac. Surg.*, 62(9):1125-30, 2004.
- Prágai, G. The use of the sublingual space. *Fogorv. Sz.*, 69(8):339-4, 1976.
- Testut, L. *Tratado de Anatomía Topográfica*. 8ª ed. Salvat, Barcelona, 1981.
- Yasumoto, M.; Nakagawa, T.; Shibuya, H.; Suzuki, S. & Satoh, T. Ultrasonography of the sublingual space. *J. Ultrasound Med.*, 12(12): 723-9, 1993.
- Yonetsu, K.; Izumi, M. & Nakamura, T. Deep facial infections of odontogenic origin: CT assessment of pathways of space involvement. *AJNR Am. J. Neuroradiol.*, 19(1):123-8, 1998.
- Correspondence to:  
Prof. Dr. Iván Suazo Galdames  
Unidad de Anatomía Normal  
Universidad de Talca  
Avenida Lircay s/n oficina N°104  
Talca - CHILE
- Fono 56-71-201576
- Email: [isuazo@utalca.cl](mailto:isuazo@utalca.cl)
- Received: 03-03-2008  
Accepted: 16-04-2008