

Contribution of Panoramic Radiographic Examinations for the Diagnosis of Root Surface Caries

Contribución de Exámenes de Radiografías Panorámicas
en el Diagnóstico de Caries Superficiales de Raíz

Marlívía Gonçalves de Carvalho Watanabe^{*}; Maria da Glória Chiarello de Mattos^{*};
Plauto Christopher Aranha Watanabe^{*} & João Paulo Mardegan Issa^{**}

WATANABE, M. G. C.; MATTOS, C. M. D.; WATANABE, P. C. A. & ISSA, M. J. P. Contribution of panoramic radiographic examinations for the diagnosis of root surface caries. *Int. J. Odontostomat.*, 1(1):17-23, 2007.

ABSTRACT: The aim of this study is to show the contribution of panoramic radiographic examinations to the epidemiologic study of root caries in patients from the Radiology Clinic at the Ribeirão Preto College of Dentistry - University of São Paulo (FORP-USP). The study's population was composed of 200 patients, 100 men and 100 women, aged over 35 years. All patients were submitted to radiographic and clinical examinations. Data regarding the Root Caries Index (RCI), obtained during the clinical examination and complemented by the panoramic radiographic examination, showed that the number of additional lesions observed with the radiographic examination significantly changed the values of the index ($p < 0.01$ - Wilcoxon), i.e., from 13.2 to 14.4. It was concluded that in spite of the panoramic radiographic examination not being ideal for the verification of the root surface caries, it might help in the diagnosis of this condition if correctly performed and using modern technology equipment.

KEY WORDS: root surface caries; clinical examination; panoramic radiographs.

INTRODUCTION

Human life expectancy has changed. People are living longer, so populations of developed countries, and also of those considered "emerging countries", have become older (Watanabe, 2003). International literature has greatly focused on the reduction of coronal caries incidence in children. However, the caries indexes in the adult and elderly population remain controversial; while some studies report advancement in oral health conditions in addition to a reduction in both edentulism and the incidence of caries incidence (Fure & Zickert, 1997; Kalsbeek *et al.*, 1998), others report the geriatric population present precarious oral health, showing a high incidence of caries, including root caries (Guivante-Nabet *et al.*, 1998; Meneghim *et al.*, 2002).

The development of surface root caries is similar to that of the coronal lesion, with the following ethiological factors: exposure of the root surface to the

oral environment (host), deficient mechanical plaque control (specific microbiota), and a cariogenic diet (substrate), which, with time, imply caries formation and progression (Banting 2001; Thylstrup and Fejerskov 2001). As to root caries, a higher incidence has been reported for adults and the elderly (Meneghim *et al.*, 2002; Banting, 2001; Vehkalahti *et al.*, 1997; Slade and Spencer, 1997). In some places, such as the South of Australia and Sweden, the occurrence of this type of lesion has been considered a risk factor for tooth loss in the age range above sixty years (Fure, 1998; Ministério da Saúde, 1988).

In Brazil, studies present a high number of tooth extractions (Ministério da Saúde, 1988; Secretaria de Estado da Saúde de São Paulo, 1999), but only a few studies report on the population's root condition. A study performed in a Southern Brazilian City, in 2002, found

* Professor, Faculty of Dentistry, University of São Paulo, Ribeirão Preto, São Paulo, Brazil.

** Graduate student, Faculty of Dentistry, University of São Paulo, Ribeirão Preto, São Paulo, Brazil.

a root caries prevalence of 3.2% among hospitalized individuals aged 50 to 75 years (Banting 2001). Thus, there is a growing need to verify root condition, with a view to a better health service delivery, since the well-known forms of caries prevention and control may be implemented in public health services.

Older patients are more prone to root caries, although estimation of the prevalence of root caries is difficult to make because of continuous loss of tooth structure with age. It has been proposed that the increased incidence of root caries in older patients may be due to the presence of periodontal disease and decreased flow of saliva, poor oral hygiene or poor health status. It has been found that 10% to 20% of root caries lesions are found subgingivally, especially at the proximal region (Hopcraft & Morgan 2006).

The clinical appearance of the root surface caries is characterized by the presence of softened and yellowish-colored dentin resulted from the loss of organic and inorganic components of dentin in the root. Although panoramic radiographs do not provide a definitive diagnosis of the presence of root surface caries, they help to detect this condition. The most important characteristic, in radiographic examination, of the root surface caries is the radiolucency in enamel reaching the dentino-enamel interface or into dentin (National Institute of Dental and Craniofacial Research 1987).

The purpose of this study was to evaluate the contribution of panoramic radiographic examinations in epidemiological studies of root caries in patients from the Radiology Clinic of the Ribeirão Preto College of Dentistry – University of São Paulo (FORP-USP).

MATERIAL AND METHOD

The study's population was composed of 200 patients, 100 men and 100 women, aged over 35 years (minimum age recommended by the WHO (OMS 1991) for studies involving adults) who had been assisted at the Radiology clinic of the FORP-USP.

Examinations: This research was a randomized double blind study.

Clinical Examination: Eighty undergraduate dentistry students, previously calibrated for this training, performed the exams. If there were any disagreements

between the clinical findings, the examiners would discuss to reach a consensus in terms of the interpretation of the criterion relating to that condition. The clinical examinations were performed on a conventional dental chair, with artificial light and using a plane dental mirror, an explorer probe #5, and a WHO periodontal probe; after a 1-minute mouth rinse with water and a later relative isolation of the dental surfaces with cotton.

Indexes, Criteria and Record: The Root Caries Index (RCI) was used, which represents the proportion of root surfaces decayed (RC) and filled among the root surfaces exposed to the oral environment, i.e, with gingival recession (GR) (Katz, 1980). The formula for the Root Caries Index is:

$$RCI = \frac{\text{Decayed surfaces} + \text{Filled surfaces}}{\text{Decayed surfaces} + \text{Filled surfaces} + \text{Sound surfaces}} \times 100$$

The following criteria were used:

A- A root surface was considered to have a gingival recession when the surface apical to the cemento-enamel junction could be visualized (Fure & Zickert, 1990).

B- A root surface was considered as being decayed when it had a darkened, discolored appearance, well defined and soft, allowing easy penetration of the explorer probe (Banting, 1980; Beck *et al.*, 1985; Fejerskov *et al.*, 1991; Katz, 1986).

C- A lesion which extended through the cemento-enamel junction was recorded as root surface caries if at least half of the extension involved the root surface (Fejerskov *et al.*, 1991).

D- A root surface was recorded as filled when it showed some kind of filling, regardless of being due to abrasion, erosion, or caries (Beck *et al.*, 1985).

E- All conventions for diagnosis proposed by Katz 1986, 1990 were adopted.

The codes for the Root Carie Index were:

- 0- missing tooth
- 1- root surface with no gingival recession
- 2- root surface with gingival recession, surface decayed
- 3- root surface with gingival recession, surface filled

- 4- root surface with gingival recession, surface sound
- 5- root surface with gingival recession and recurrent caries
- 6- root surface with gingival recession and caries neighboring coronal restoration
- 7- root surface with gingival recession and additional lesions
- X- "illegible" surface

1.2. Radiographic Examination. Radiographic examinations were performed by a member of the Radiology Discipline at FORP-USP, using panoramic radiographs obtained with the Ortophos X-ray apparatus of Sirona Dental. The radiographic process was done manually, based on the time/temperature method.

In order to assess the radiographs, they were placed on a black interpretation card. This card was interpreted by the examiner by laying it on an illuminator with a magnifying lens in a completely dark environment.

The radiographic criteria used to define the root surface caries is the radiolucency in the cemento-enamel junction or into dentin.

Radiographic Interpretation Criteria and Records: The same criteria for clinical examinations were used, respecting the particularities of the radiographic examination. The examiners observed if the radiolucency in enamel reached the dentino-enamel interface or into dentin, and classified the radiographs

accordingly. The examiners had no information about the clinical data.

Statistical analysis: The results were analyzed using the Mann-Whitney test and values of $p < 0.01$ were considered statistically significant.

RESULTS AND DISCUSSION

A recent research, conducted at the clinics of the Ribeirão Preto College of Dentistry – University of São Paulo, involving 360 patients of both genders, in the group ages 35 to 44 years and 50 to 59 years, reported that 98.89% of those patients showed root surfaces exposed to the oral cavity, i.e., with gingival recession, and 78.06% had at least one root lesion, treated or not (Watanabe, 1995). The Root Caries Index (RCI) proposed by Katz (1980), which describes the risk of developing the disease once the root surface being exposed, was 16.67%, which is in accordance with what has been estimated for populations of western developed countries (Katz 1985).

In the present study, 55 patients (27.5%) showed new root surface caries lesions after radiographic examination (Figs. 1,2). This proportion was larger for men (42.5%) than for women (17.7%). A total of 110 new mesial and distal lesions were detected, which corresponds to 46.61% of the proximal lesions and 15% of all lesions observed in all surfaces by clinical examination (Fig. 3). A similar study also showed a

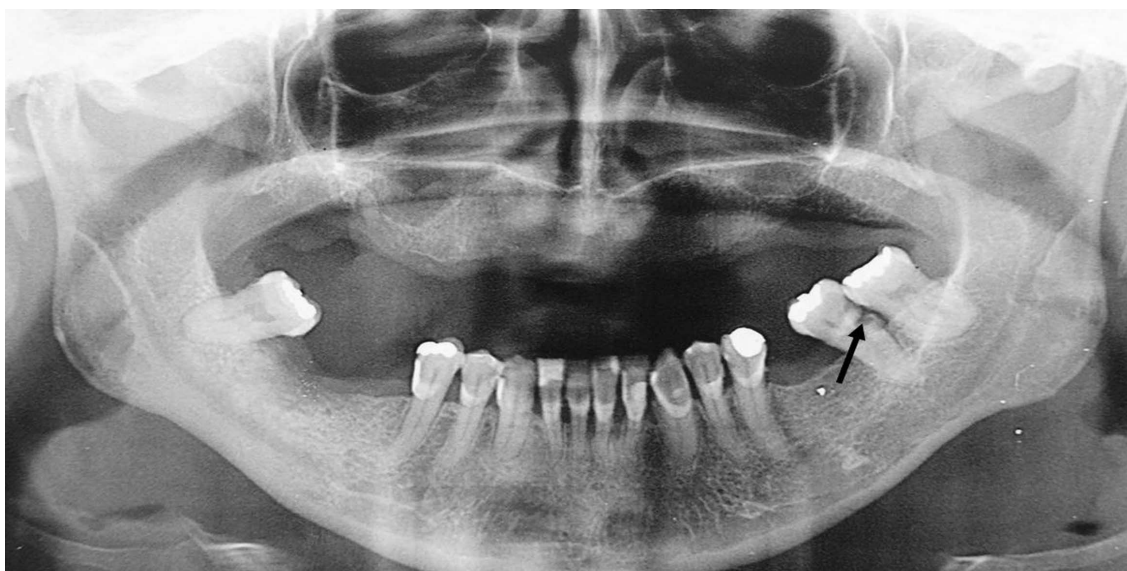

Fig. 1. Root surface carie lesion (arrow) in a posterior tooth panoramic radiographic examination.

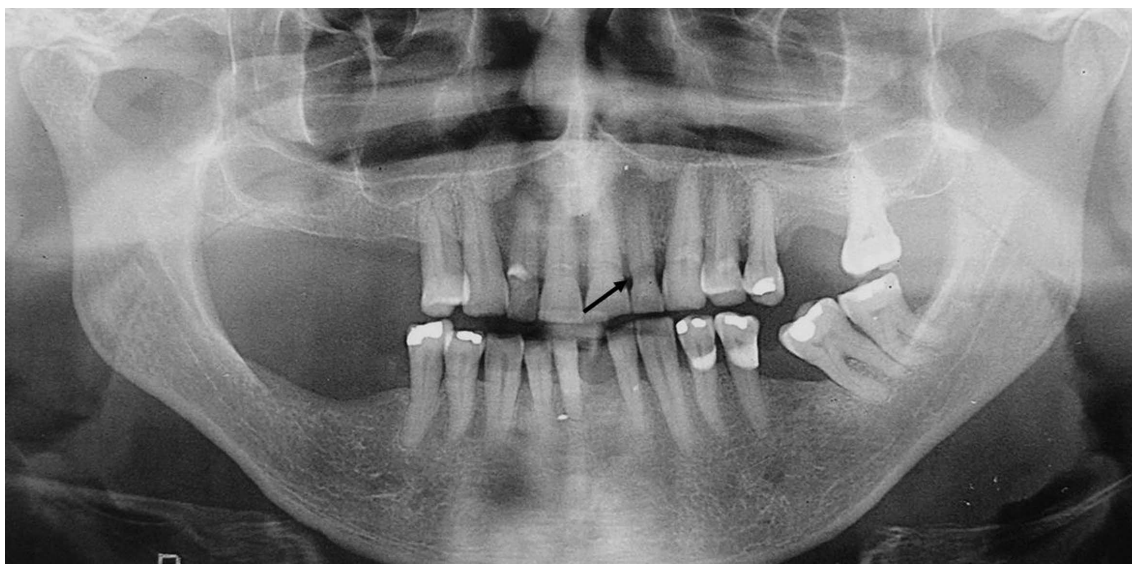


Fig. 2. Root surface carie lesion (arrow) in an anterior tooth panoramic radiographic examination.

significant proportion of additional lesions detected radiographically (42%) in relation to mesial and distal lesions. However, distal lesions represented only 3.9% of the total (Sumney *et al.*, 1973). On the other hand, no additional lesions were observed by examining the radiographs of 91 patients aged over 60 years (Fejerskov *et al.*, 1991) (Fig. 4).

Compared to the clinical examination alone, there was a significant increase in the detection of caries lesions (CL) when the radiographic examination was also performed ($p < 0.01$); this was observed especially for men. Although not statistically significant, there also was a difference in relation to the gingival

recession index (GR) when one or both examinations (clinical and radiographic) were performed, for both genders. The root caries index (RCI) was significantly changes, for both genders, after performing both examinations (clinical and radiographic) ($p < 0.01$).

All the patients of this study presented a normal medical history, but some medical conditions such as Sjogren's syndrome, pharmacological agents with xerostomic side effects, and therapeutic radiation to the head and neck, may lower the salivary flow rate to pathological levels and dramatically elevate a patient's risk of caries. This suggests that normal salivary flow rate is protective against caries. Some

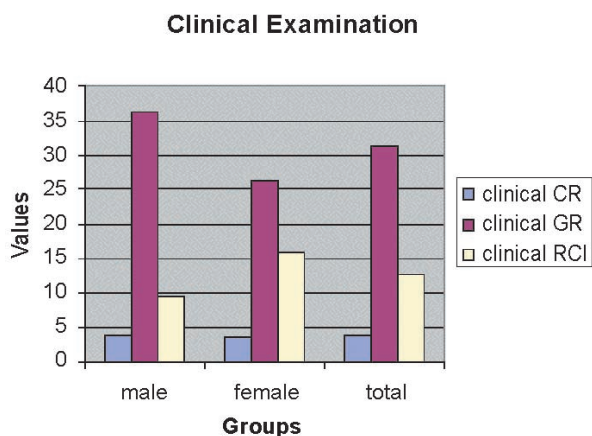


Fig. 3. Values of the CR, GR and RCI after clinical examination. ($p < 0.01$)

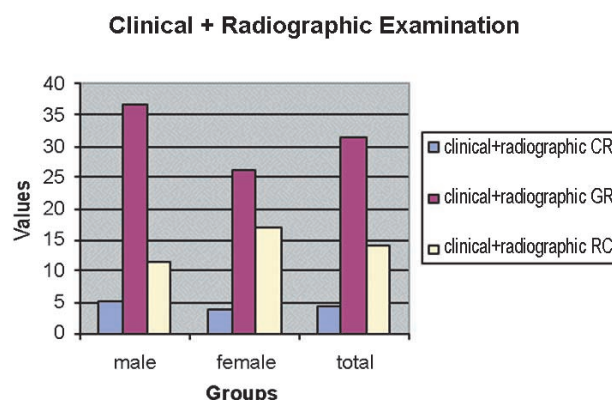


Fig. 4. Values of the CR, GR and RCI after clinical + radiographic examination. ($p < 0.01$)

studies indicate that a low buffering capacity, low salivary IgA, and low salivary calcium and phosphate are in some way linked to increased caries as well. While some of the risk indicators known for children may be well applied for all ages, some may differ in the way they act or in their degrees of importance, while other risk indicators should be specific for the adult and elderly populations. Thus, the inability to maintain good oral hygiene and xerostomia are risk factors of special significance among the elderly, and gingival recession uniquely increases the risk of root caries in elderly populations by exposing previously protected root surfaces to cariogenesis (Boutsis *et al.*, 2000; Shah & Sundaram 2004).

Most recent studies have shown that *Streptococcus mutans*, *S. sobrinus* and *Actinomyces* species are responsible for surface root caries. Zambon and Kasprzak 1995 described the pathogenesis of root caries formation. The process begins with colonization by acid-producing bacteria plaque, which is followed by the formation of demineralized clefts in the cementum. In the next step, Gram-positive bacteria invade the dentinal tubules, which lead to the formation of microcavities, sclerosis, crystal growth, demineralization of the dentinal tubules and destruction of the organic matrix. This process may be enhanced in the presence of gingival recession (Zambon and Kasprzak 1995), corroborating with this study which found a high level for gingival recession, especially in the male group. The authors also found that root caries spread in a circumferential manner. Clinically, root caries appear as soft, irregularly shaped lesions, either entirely confined to the root surface or also involving the enamel at the cemento-enamel junction. However, clinically, the lesions start on the root surface. Radiographically, it was found in this study that root surface caries are characterized by a radiolucency in the cemento-enamel junction or into dentin, which is in accordance to Locker's studies.

An aspect approached in relation to the difficulties of radiographically diagnosing root surface caries was the possibility of having an image overlay of the lesions on the vestibular and lingual surfaces (Jordan and Sumney 1973). In this study, 8.47% of the teeth in which new proximal lesions were observed after radiographic examination showed vestibular and/or lingual (palatines) lesions.

The results of this study, therefore, corroborate with other studies involving previously taken

radiographs, which state that, taking ethical aspects into consideration, such radiographs should be used as a complementary procedure of clinical examinations for the assessment of root surface caries (Katz 1990; Flint *et al.* 1998; Amerise *et al.* 2001).

It is acknowledged that the best complementary examination for research on caries, mainly interproximal caries, is radiographic examination; due to the interproximal radiographic technique in addition to the periapical radiographic examination (Katz 1986; Bloemendal *et al.* 2004). Furthermore, when the panoramic radiographs are technically well performed using modern X-ray equipment, such as elipsopantomography, it is possible to increase diagnostic accuracy for these lesions, particularly of the posterior region, as shown in this study. The main disadvantage of panoramic radiographs concerning their inherent limitation, due to the great distance between the planes of the object and the film, the many degrees of distortion during the orbit of the equipment, and to the presence of intensifying screens, was largely diminished by the new technology of modern equipment. An example of such equipment is the ORTOPHOS, which maintains the distance object/film the closest possible thanks to the reading performed by a microprocessor over the patients' cranium and also to the recent technology of tablet grains used in the relation radiographic films/intensifying screens.

Finally, it is important to state that the panoramic radiographic examination, when available, may be used as a complementary procedure for assessing the presence of caries on root surfaces, thus, facilitating the planning, treatment, and follow up of health conditions for health professionals of both public and private systems (Neal and Bowden 1988; Watanabe *et al.* 1997; Pretty and Maupome 2004). The panoramic radiographic examination, in this study, contributed significantly for the detection of proximal lesions, changing the Root Caries Index (RCI) obtained clinically. In addition, the radiographic examination reveals the level of supporting alveolar bone, condition of the interproximal crest, length and shape of roots, bone loss in furcations and calculus deposits, as well as described by Leake (2001). Thus, despite the panoramic radiographic exam not being ideal for the verification of caries, as the interproximal radiographic examination would be, it could contribute significantly, as it was showed in this study, to the assessment of such a condition, when performed with the correct technique and using modern equipment.

WATANABE, M. G. C.; MATTOS, C. M. D.; WATANABE, P. C. A. & ISSA, M. J. P. Contribución de exámenes de radiografías panorámicas en el diagnóstico de caries superficiales de raíz. *Int. J. Odontostomat.*, 1(1):17-23, 2007.

RESUMEN: El objetivo de este estudio es demostrar la contribución de exámenes de radiográficas panorámicas al estudio epidemiológico de la carie de raíz en pacientes de la clínica de la radiología en la Facultad de Odontología de Ribeirão Preto de la Universidad de São Paulo (FORP-USP). La población del estudio fue de 200 pacientes, 100 hombres y 100 mujeres, con más de 35 años. Sometieron a todos los pacientes a exámenes radiográficos y clínico. Los datos con respecto a la carie de raíz ponen en un índice (RCI), obtenido durante el examen clínico y complementado por el examen radiográfico panorámico, demostrando que el número de las lesiones adicionales observadas con la examinación radiográfica cambió perceptiblemente los valores del índice (p Wilcoxon), es decir, a partir la 13.2 a 14.4. Fue concluido que a pesar del examen radiográfico panorámico no ser ideal para la verificación de la carie de superficie de la raíz, puede ser que ayude en el diagnóstico de este tipo de lesión cuando realizado correctamente y con equipo moderno de la tecnología.

PALABRAS CLAVE: carie superficial de raíz, examen clínico, radiografías panorámicas.

REFERENCES

- Amerise, C.; Delgado, A.M.; Romero, S. & Santana, M. Clinical-radiographic correlation in occlusal surfaces. *Acta. Odontol. Latinoam.*, 14:40-5, 2001.
- Banting, D. W.; Ellen, R. P. & Fillery, E. D. Prevalence of root surface caries among institutionalized older persons. *Community. Dent. Oral. Epidemiol.*, 8:84-8, 1980.
- Banting, D.W. The diagnosis of root caries. *J. Dent. Educ.* 65:991-6, 2001.
- Beck, J.D.; Hunt, R.J.; Hand, J.S. & Field, H.M. Prevalence of root and coronal caries in a noninstitutionalized older population. *J. Am. Dent. Assoc.*, 111:964-7, 1985.
- Bloemendal, E.; de Vet, H.C.; Bouter, L.M. The value of bitewing radiographs in epidemiological caries research: a systematic review of the literature. *J. Dent.* 32:255-64, 2004.
- Boutsi, E. A.; Paikos, S.; Dafni, U.G.; Moutsopoulos, H. M. & Skopouli, F.N. Dental and periodontal status of Sjogren's syndrome. *J. Clin. Periodontol.*, 27:231-5, 2000.
- Fejerskov, O.; Luan, W.M.; Nyvad, B.; Budtz-Jorgensen, E. & Holm-Pedersen, P. Active and inactive root surface caries lesions in a selected group of 60- to 80-year-old Danes. *Caries. Res.*, 25:385-91, 1991.
- Fernandes, R. A. C.; Silva, S.R.C.; Watanabe, M.G.C.; Pereira, A. C. & Martildes, M.L.R. Uso e necessidade de prótese dentária em idosos que demandam um centro de saúde. *Rev. Bras. Odontol.*, 54:107-10, 1997.
- Flint, D. J.; Paunovich, E.; Moore, W. S.; Wofford, D.T. & Hermes, C. B. A diagnostic comparison of panoramic and intraoral radiographs. *Oral. Surg. Oral. Med. Oral. Pathol. Oral. Radiol. Endod.*, 85: 731-5, 1998.
- Fure, S. & Zickert, I. Root surface caries and associated factors. *Scand. J. Dent. Res.*, 98:391-400, 1990.
- Fure, S. & Zickert, I. Incidence of tooth loss and dental caries in 60-, 70- and 80-year-old Swedish individuals. *Community. Dent. Oral. Epidemiol.*, 25:137-42, 1997.
- Fure, S. Five-year incidence of caries, salivary and microbial conditions in 60-, 70- and 80-year-old Swedish individuals. *Caries. Res.*, 32:166-74, 1998.
- Guivante-Nabet, C.; Tavernier, M.; Trevoux, C.; Berdal, A. Active and inactive caries lesions in a selected elderly institutionalized French population. *Int. Dent. J.*, 48:111-22, 1998.
- Hopcraft, M. S. & Morgan, M.V. Pattern of dental caries experience on tooth surfaces in an adult population. *Community. Dent. Oral. Epidemiol.*, 34:174-83, 2006.
- Jordan, H. V. & Sumney, D.L. Root surface caries: review of the literature and significance of the problem. *J. Periodontol.*, 44:158-63, 1973.

- Kalsbeek, H.; Truin, G.J.; van Rossum, G.M.; van Rijkom, H.M.; Poorterman, J.H.; Verrips, G.H. Trends in caries prevalence in Dutch adults between 1983 and 1995. *Caries. Res.*, 32:160-5, 1998.
- Katz, R. V. Assessing root caries in populations: the evolution of root caries index. *J. Public. Health. Dent.*, 40: 7-16, 1980.
- Katz, R. V. Root caries. Is it the caries problem of the future? *J. Can. Dent. Assoc.*, 51: 511-5, 1985.
- Katz, R. V. The clinical identification of root caries. *Gerodontology*, 5:21-4, 1986.
- Katz, R. V. Clinical signs of roots caries: measurement issues from an epidemiologic perspective. *J. Dent. Res.* 69:1211-5, 1990.
- Leake, J. L. Clinical decision-making for caries management in root surfaces. *J. Dent. Educ.*, 65: 1147-53, 2001.
- Locker, D.; Mscn, E. W. & Jokovic, A. What do older adults' global self-ratings of oral health measure? *J. Public. Health. Dent.*, 65:146-52, 2005.
- Meneghim, M.C.; Pereira, A.C. & Silva, F. R. B. Prevalência de cárie radicular e condição periodontal em uma população institucionalizada de Piracicaba - SP. *Pesq. Odontol. Bras.*, 16:50-6, 2002.
- Ministério da Saúde. *Levantamento epidemiológico em saúde bucal: Brasil, zona urbana, 1986*. Brasília: Divisão Nacional de Saúde Bucal, Ministério da Saúde; 1988.
- National Institute of Dental and Craniofacial Research. *Oral health of US adults*. Bethesda, Maryland, National Institute of Health, 1987.
- Neal, J. J. & Borden, D.E. The diagnostic value of panoramic radiographs in children aged nine to ten years. *Br. J. Ortod.*, 15:193-7, 1988.
- OMS. *Levantamento epidemiológico básico de saúde bucal. Manual de instruções*. 3.ed. São Paulo, Editora Santos; 1991.
- Pretty, I. A. & Maupome, G. A. Closer look at diagnosis in clinical dental practice: part 3. Effectiveness of radiographic diagnostic procedures. *J. Can. Dent. Assoc.*, 70:388-94, 2004.
- Secretaria de Estado da Saúde de São Paulo. *Levantamento epidemiológico em saúde bucal: Estado de São Paulo, 1998*. São Paulo: Secretaria de Estado da Saúde de São Paulo; 1999.
- Shah, N. & Sundaram, K. R. Impact of socio-demographic variables, oral hygiene practices, oral habits and diet on dental caries experience of Indian elderly: a community-based study. *Gerodontology*, 21:43-50, 2004.
- Slade, G. D. & Spencer, A. J. Distribution of coronal and root caries experience among persons aged 60+ in South Australia. *Aust. Dent. J.*, 42:178-84, 1997.
- Sumney, D.L.; Jordan, H.V. & Englander, H.R. The prevalence of root surface caries in selected populations. *J. Periodontol.*, 44:500-4, 1973.
- Thylstrup, A. & Fejerskov, O. *Cariologia clínica*. São Paulo, Editora Santos; 2001.
- Watanabe, M. G. C. Root caries prevalence in a group of Brazilian adult dental patients. *Br. Dent. J.*, 14:153-6, 2003.
- Watanabe, M. G. C. *Experiência de cárie de superfície radicular em adultos atendidos na FORP-USP de 1993-1994*. [Master's thesis]. São Paulo: Faculdade de Saúde Pública da Universidade de São Paulo, 1995. 68p.
- Watanabe, P. C. A.; Souza, J. G.; Almeida, S. M. Estudo radiográfico (ortopantomográfico) da incidência das anomalias dentais de número na região de Piracicaba-S.P. *ROBRAC*, 6:32-7, 1997.
- Vehkalahti, M. M.; Virbic, V. L.; Peric, L. M. & Matvoz, E.S. Oral hygiene and root caries occurrence in Slovenian adults. *Int. Dent. J.*, 47:26-31, 1997.
- Zambon, J. J.; Kasprzak, S. A. The microbiology and histopathology of human root caries. *Am.J. Dent.*, 8: 323-8, 1995.
- Correspondence to:
João Paulo Mardegan Issa
Depto. de Morfologia, Estomatologia e Fisiologia
Faculdade de Odontologia de Ribeirão Preto
Av. Café S/N, CEP: 14040-904
Ribeirão Preto-SP - BRAZIL.
- Phone: +55 16 9717-0509 or 3602-4095
- E-mail: jpmisssa@forp.usp.br
- Received: 02-04-2007
Accepted: 28-05-2007

El cepillo Interprox más pequeño del mercado

* **NUEVO**

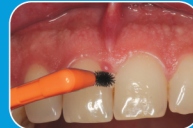

interprox[®]
plus
super micro

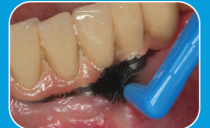**Más pequeño,
más accesible**

¿Cuándo utilizar
interprox[®]?

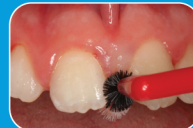Espacios
interproximales



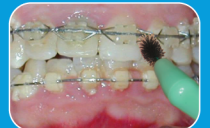Implantes



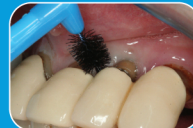Diastemas



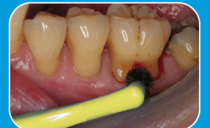Ortodoncia



Prótesis fijas

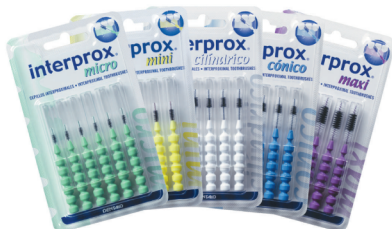

Zonas furcales



La gama más completa de
cepillos interproximales

interprox.



**interprox.
plus**



**interprox.
access**



Laboratorios
DENTAID S.A.
Expertos en Salud Bucal
www.dentaid.com